

# Clinical and microbiological efficacy of chlorine dioxide in the management of chronic atrophic candidiasis: an open study

Abdel R. Mohammad  
Columbus, USA

Peter J. Giannini  
Philadelphia, USA

Philip M. Preshaw  
Newcastle upon Tyne, UK

Howard Alliger  
Melville, USA

**Objective:** To assess the clinical and microbiological efficacy of chlorine dioxide (ClO<sub>2</sub>) as a topical antiseptic for the treatment of chronic atrophic candidiasis in geriatric patients. **Participants:** Thirty patients with chronic atrophic candidiasis. **Methods:** Patients were instructed to rinse the mouth with 0.8% ClO<sub>2</sub> mouth rinse (DioxiDent) twice daily for one minute and to soak their dentures overnight in the ClO<sub>2</sub> for 10 days. Patients were evaluated both clinically and microbiologically at baseline and after 10 days, and any significant side effects were recorded. The clinical appearance of the oral soft tissues was scored on a scale of 0–3 (0 indicating no clinical signs, 1 indicating involvement of < 25% of the palatal mucosa, 2 indicating involvement of 25–50% of the palatal mucosa, and 3 indicating marked erythema involving > 50% of the palatal mucosa). Microbiological testing was undertaken to determine the number of colony forming units (CFUs) of *Candida albicans*. **Results:** ClO<sub>2</sub> significantly improved the clinical appearance and microbial count ( $p < 0.001$ ) after treatment, without significant side effects. Results showed marked improvement in the clinical appearance of the tissues after 10 days, with total resolution in the majority of cases. The total CFU/ml ranged from 15,000–53,000 at baseline and was reduced to  $\leq 500$  after 10 days of treatment ( $p < 0.001$ ). The mean clinical score was 2.50 at baseline, and was reduced to 0.17 after 10 days of treatment ( $p < 0.001$ ). **Conclusions:** Within the limitations of this pilot study, the effectiveness of topical chlorine dioxide (0.8%) in the management of chronic atrophic candidiasis was demonstrated. ClO<sub>2</sub> provided a safe and clinically effective option in the management of chronic atrophic candidiasis.

*Key words:* Candidiasis, chlorine dioxide, antifungals, *Candida albicans*

*Candida albicans* can be found in the normal oral microflora of 30–50% of the population<sup>1</sup>. In a healthy individual, the inherent microflora usually suppresses the overgrowth of pathogenic fungal organisms and the intact mucosal lining prevents the seeding of these organisms. In the elderly population, oral candidiasis is a common infection. Several conditions can predispose to the development of candidiasis. These include the use of broad-spectrum antibiotics, immunosuppression, xerostomia, physical disabilities that impair oral hygiene or proper nutrition, as well as use of removable oral prostheses. Other factors which may contribute to the development of candidiasis include decreased salivary flow rate, head and neck irradiation, and endocrinopathies such as diabetes mellitus<sup>2,3</sup>. An accurate diagnosis may be achieved by a combination of clinical features, cultures and smears, and is frequently confirmed by a response to antifungal therapy<sup>4</sup>.

Candidiasis is the fourth leading cause of septicaemia in the United

Correspondence to: Dr. Abdel Rahim Mohammad, The Ohio State University College of Dentistry, Section of Primary Care, Postle Hall Office 3058, 305 West 12<sup>th</sup> Avenue, Columbus, OH 43210, USA. E-mail: mohammad.6@osu.edu

States<sup>5</sup>. Candidal infections seem to occur at disproportionately high rates in those who are 65 and older. Complications from candidal septicaemia include retinal, renal, splenic, pulmonary and hepatic damage<sup>5</sup>. Candidal septicaemia is rare in the immunocompetent individual, but can be fatal in those who are immunocompromised and lack the necessary host defences to eradicate this pathogenic fungus<sup>6</sup>. A high risk of fatality (27%) associated with systemic candidal infections has been reported in leukaemic patients<sup>7</sup>. Previous studies have indicated the importance of early diagnosis and treatment in preventing systemic candidal infection and complications such as multiple organ failure<sup>7</sup>. Early treatment with an effective topical antifungal agent could eliminate the need for more potent systemic treatments such as fluconazole, ketoconazole or amphotericin B<sup>7</sup>.

Candidiasis is frequently noted in the HIV-positive population. Pseudomembranous candidiasis is the most common form of oral and oesophageal candidiasis that is observed in HIV-positive individuals with initial and progressive immune suppression, usually with CD4+ cell counts < 400 cells/mm<sup>3</sup>. Erythematous or atrophic candidiasis is most commonly seen during the early stages of HIV disease, typically in combination with the pseudomembranous form. Hyperplastic candidiasis is most often associated with severe immune suppression as seen in long standing HIV disease<sup>8</sup>.

Current modes of therapy in immune competent and HIV-positive patients may consist of topical agents such as clotrimazole troches, nystatin pastilles, or nystatin suspension. The utilisation of topical antifungal therapies requires adequate contact time with the oral tissues, at least two minutes five times per day, over a 7–14 day period<sup>9</sup>. Systemic medications, which are more often utilised in the treatment of candidiasis in the immune

compromised patient, include fluconazole, ketoconazole, itraconazole, and amphotericin B. Systemic agents have the advantage of a single daily dose regimen, and are effective in patients with both oesophageal and oral candidiasis. Ketoconazole was the first systemic antifungal to be introduced for the treatment of candidal infections refractory to topical agents<sup>3</sup>. Side effects of ketoconazole, such as impaired metabolism of warfarin and cyclosporine as well as decreased effectiveness of medications such as isoniazid, rifampin, and phenytoin, are potential contraindications for the use of this drug. Fluconazole has an advantage over ketoconazole, as well as itraconazole, in that it does not require an acidic environment for absorption. Antifungal prophylaxis with systemic agents is often indicated for high-risk HIV-positive patients, typically those with a CD4+ cell count < 200 cells/mm<sup>3</sup>. The main disadvantages with prophylactic antifungal medications such as fluconazole are cost and the potential development of fluconazole resistant strains of *Candida*<sup>9</sup>.

Chlorine dioxide is a potential alternative topical treatment for oral candidiasis. The antiseptic effects of chlorine dioxide (ClO<sub>2</sub>) have previously been investigated<sup>10,11</sup>. Prior studies have demonstrated its effectiveness as a disinfectant<sup>10</sup>. Chlorine dioxide has been shown to be effective as a topical agent by killing bacteria, viruses, and fungi in less than one minute<sup>10</sup>. The efficacy of ClO<sub>2</sub>-containing solution was proven for the treatment of wounds infected by *Pseudomonas aeruginosa* as well as burn wounds in mice<sup>12</sup>. It has also been utilised in oral health care products for the management of periodontitis<sup>13</sup>. ClO<sub>2</sub>, however, has not been studied as a treatment for candidiasis.

Chlorine dioxide has been shown to be a non-toxic agent. Previous studies assessed the effects of ClO<sub>2</sub> in concentrations of up to 100ppm, which is the same

concentration of ClO<sub>2</sub> that is found in DioxidDent rinse. When studying the effects of ClO<sub>2</sub> in a rat model at this concentration, there were no signs of foetal malformations following ingestion of ClO<sub>2</sub> and no observed local or systemic side effects following topical application<sup>14-16</sup>. In addition, a diluted ClO<sub>2</sub> solution was tested at the cellular level. Incubation of ClO<sub>2</sub> with HIV infected CD4+ cells in tissue culture demonstrated inactivation of the HIV virus with minimal effect to the CD4 cells<sup>17</sup>.

The aim of this observational study was to investigate the effectiveness of chlorine dioxide as a topical therapeutic agent for the treatment of chronic atrophic candidiasis.

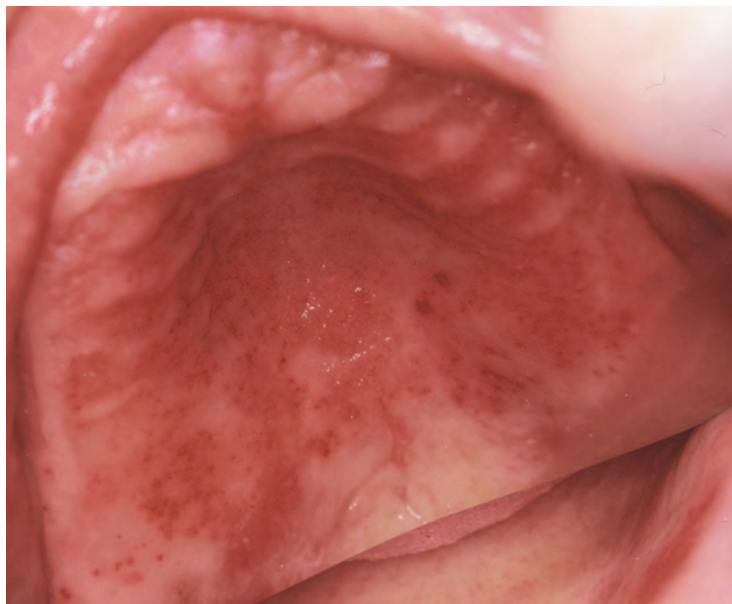## Materials and methods

The medical history of potentially eligible patients who were wearing complete dentures was recorded, including the use of any xerostomic medications. Excluded were patients with a history of an impaired immune system, diabetes mellitus, and those on immunosuppressive medications, including steroid therapy. Based on the information from the health history and initial clinical examination, 30 patients with a positive diagnosis of chronic atrophic candidiasis were included in the study. A clinical examination was conducted to assess the extent of the oral lesions. The clinical appearance of the oral soft tissue was given a score on a scale of 0–3, with 0 indicating no clinical signs, 1 indicating involvement of < 25% of the palatal mucosa, 2 indicating involvement of 25–50% of the palatal mucosa, and 3 indicating marked erythema involving > 50% of the palatal mucosa. An assessment of unstimulated whole saliva was made on each patient. Xerostomic patients with unstimulated salivary flow rates of < 0.1ml/min were excluded from the study.

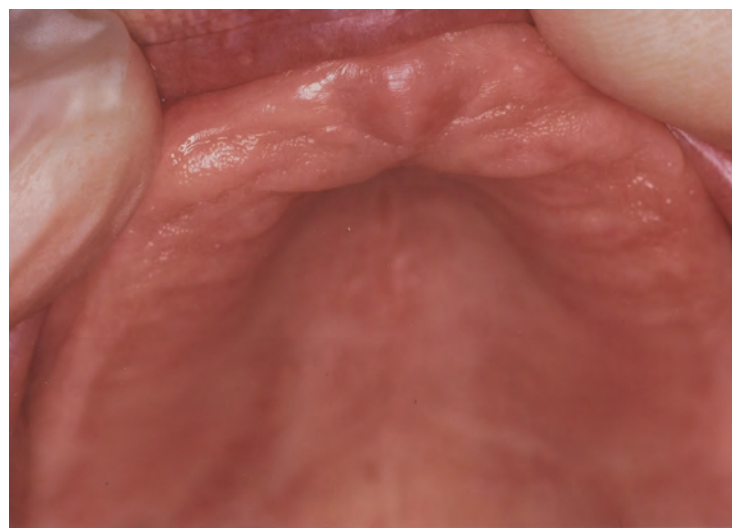One millilitre of unstimulated whole saliva was collected by

expectoration into a plastic cup from each patient. A quantitative microbiological test was then performed to establish a baseline value for the presence of *Candida albicans*. The saliva sample was used to inoculate a Sabouraud agar plate using a 0.01ml sterile loop. Colony forming units (CFUs) were determined according to a set protocol<sup>18</sup>. Thus, after a 3-day incubation period at room temperature, the number of colonies on each plate was counted and multiplied by 100 to determine the CFU/ml. In addition, swabs of both the soft tissues and the tissue surface of the denture were obtained to inoculate a second Sabouraud agar plate as a qualitative assessment of the presence of *Candida albicans*. The patients were instructed to wear their dentures during the day while performing the treatment. They were, however, instructed to remove their dentures at night and soak them in the DioxiDent.

Patients were examined at baseline and 10 days after treatment. We chose to examine the patients at these time intervals to be able to assess the effectiveness of DioxiDent within the same timeframe as that of the known effectiveness of currently used topical antifungal medications. Each patient received the chlorine dioxide medication, 0.8% (DioxiDent – Frontier Pharmaceutical, Inc., Melville, New York, USA), which was supplied in the form of two liquids. The active ingredient in part A consisted of sodium chlorite and in part B consisted of a weak acid. The combination of equal parts of A and B yields chlorine dioxide as the product. Patients were instructed to mix approximately 15ml of each of the two parts, A and B, of the DioxiDent, to rinse the mouth with it, to keep it in contact with the tissues for 1 minute and then expectorate. Patients repeated this twice daily, in the morning and at bedtime. In addition, patients were instructed to soak their dentures in the ClO<sub>2</sub> mixture overnight. Any



**Figure 1.** Before treatment. Chronic atrophic candidiasis (oral soft tissues score grade 3) and salivary count of 40,000 CFU/ml.



**Figure 2.** After treatment. Same patient as in Figure 1 after 10 days of using 0.8% chlorine dioxide mouth rinse. Clinical oral score now grade 0, with salivary count of 370 CFU/ml.

unwanted effects were recorded at each visit. The lag time between use of the ClO<sub>2</sub> and sampling was 6 hours.

#### **Statistical analyses**

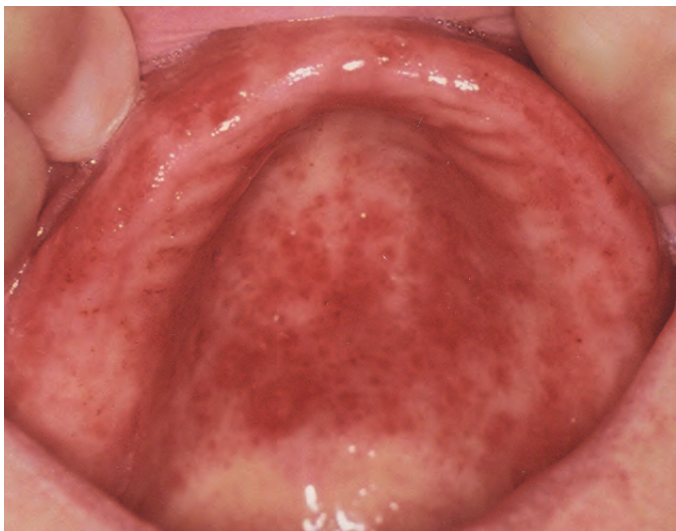The mean clinical scores (oral soft tissue appearance) and mean microbial count (CFU/ml)  $\pm$  standard deviation (SD) were calculated before and after treatment. Non-parametric tests (Wilcoxon Signed-Rank) were used to test for statistically significant differences in mean

clinical oral soft tissue scores and microbial counts between baseline and day 10. Statistical significance was accepted at  $p < 0.05$ . All analyses were performed using SPSS version 10 (SPSS, Inc., Chicago USA) software package.

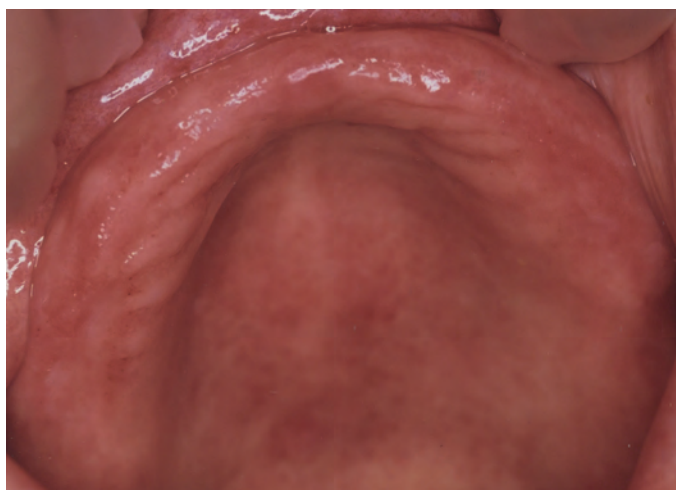
#### **Results**

The data demonstrated a marked clinical improvement after 10 days of treatment, with complete resolution in a majority of patients (Figures 1–4). There was a statisti-





**Figure 3.** Before treatment. Chronic atrophic candidiasis (oral soft tissues score grade 3) and salivary count of 52,000 CFU/ml.



**Figure 4.** After treatment. Same patient as in Figure 3 after 10 days of using 0.8% chlorine dioxide mouth rinse. Clinical oral score now grade 1, with salivary count of 450 CFU/ml.

**Table 1** Mean oral soft tissue data (clinical appearance) and microbial count at baseline and day 10

	Clinical appearance Mean (SD), range	Microbial count (CFU/ml) Mean (SD), range
Baseline	2.50 (0.73), 1.00–3.00	41,933 (13,019), 15,000–53,000
Day 10	0.17 (0.38), 0.00–1.00	329 (106), 100–500

cally significant correlation between recorded oral soft tissue scores and the microbial count ( $r^2 = 0.95$ ,  $p < 0.001$  – data not shown). Mean baseline and day 10 data are presented in Table 1. Analyses showed that chlorine dioxide had a highly statistically significant effect on improving the clinical appearance of the chronic atrophic candidiasis, with mean oral soft

tissue scores reduced from 2.50 at baseline to 0.17 after 10 days ( $Z = -4.88$ ,  $p < 0.001$ ). Of the 30 patients, oral soft tissue scores of 0 (representing no clinical signs of candidiasis) were recorded in 25 patients (83.3%) after 10 days of treatment. A highly statistically significant reduction in the microbial count was also noted and the baseline mean microbial count of

41,933 CFU/ml was reduced to 329 after 10 days of treatment with chlorine dioxide ( $Z = -4.78$ ,  $p < 0.001$ ). No significant side effects were reported during the course of treatment, and there was no evidence of any effects of  $\text{ClO}_2$  on denture materials.

### Discussion

The diagnosis of oral candidiasis requires clinical examination, and may also be supported with laboratory tests. The first line of treatment for chronic atrophic candidiasis involves removing the dentures at night, improving denture hygiene, and possibly modifying the denture. In this study,  $\text{ClO}_2$  was used both as a topical antiseptic and for soaking the dentures overnight after they had been removed from the mouth. Pharmaceutical treatment options for the management of fungal infections have been developing since the early 1900s. One of the first topical preparations was gentian violet. This was used until 1951, when the first polyene antibiotic, nystatin, was introduced. In 1956 it was reported that amphotericin had antifungal properties. The azole class of antifungals were introduced in 1944 and were the primary treatment modalities in use from the late 1960s to the mid-1980s. These include miconazole, clotrimazole, ketoconazole, fluconazole, and itraconazole, which are also commonly used today<sup>2</sup>. More recently, voriconazole has been introduced as an additional systemic agent<sup>2</sup>.

The antiseptic effects of chlorine dioxide ( $\text{ClO}_2$ ) have been demonstrated in previous studies and  $\text{ClO}_2$  has been shown to be effective as a topical agent<sup>10</sup>. The mechanism of action of  $\text{ClO}_2$  at low concentrations is thought to result from the disruption of protein synthesis and enzyme inactivation. Clinical applications of  $\text{ClO}_2$  include the successful treatment of otherwise non-healing diabetic ulcers. Chlorine dioxide has

also been shown to be effective as an antibacterial for oral soft tissues following periodontal osseous surgery<sup>13</sup>. Another study assessed the effectiveness of chlorine dioxide in the disinfection of acrylic resin strips infected with *Candida albicans*, *Staphylococcus aureus* and *Escherichia coli*. When compared with 5.25% sodium hypochlorite diluted 1:10, chlorine dioxide demonstrated complete disinfection in 2 minutes, compared with 4 minutes for the sodium hypochlorite<sup>11</sup>.

The antiseptic properties of ClO<sub>2</sub> that were demonstrated by previous studies prompted the current pilot study for the use of this product in the treatment of chronic atrophic candidiasis. This condition affects a majority of denture wearers<sup>3</sup>, and a cost-effective, easily applied and clinically effective treatment would clearly be of benefit in this population. The data reflect the benefits that ClO<sub>2</sub> rinse provides in patients with chronic atrophic candidiasis, and the clinical benefits are clear from *Figures 1–4*. We propose that the improvements afforded by ClO<sub>2</sub> treatment are not only highly statistically significant (*Table 1*), but are also clinically significant, with clinical resolution in the great majority of cases (> 80%) and a reduction in mean microbial counts of more than two orders of magnitude. These changes represent a real and tangible benefit to patients after a very short treatment period.

Chlorine dioxide has the added benefit of possessing general antiseptic properties and stimulating the host tissue response against infection<sup>12</sup>. The action of ClO<sub>2</sub>-containing solution on *Pseudomonas aeruginosa* infected wounds in mice revealed better biocidal activity when compared to chlorhexidine or silver sulfadiazine preparations<sup>12</sup>. Chlorine dioxide has also been shown to be effective in promoting soft tissue healing<sup>13</sup>. Studies have also demonstrated the effectiveness of chlorine dioxide in the treatment of halitosis. The effectiveness

of chlorine dioxide not only results from its antimicrobial properties, but also its ability to oxidise volatile sulphur compounds which are produced by bacteria<sup>19,20</sup>. Some of the features that distinguish chlorine dioxide from current antifungal medications include its broad-spectrum antiseptic ability, as well as its anti-inflammatory properties. ClO<sub>2</sub> may also have a role in minimising the risk of developing azole resistance in patients with candidal infection<sup>9</sup>. This is of particular relevance as azole-resistant strains of candida can be transmitted between family members. Other advantages of chlorine dioxide as an antifungal agent include reduced cost and ease of use.

Since ClO<sub>2</sub> appears effective in the treatment of chronic atrophic candidiasis, further investigation of this agent is warranted. Future studies will aim to compare the effectiveness of chlorine dioxide to current standard treatment modalities for chronic atrophic candidiasis.

## Conclusions

Within the limitations of this pilot study, the results provide evidence for the safety and clinical and microbiological effectiveness of the topical antiseptic chlorine dioxide (0.8%) in the management of chronic atrophic candidiasis.

## References

1. Arendorf TM, Walker DM. The prevalence and intra-oral distribution of *Candida albicans* in man. *Arch Oral Biol* 1980 **25**: 1–10.
2. Epstein J, Polsky B. Oropharyngeal candidiasis: A review of its clinical spectrum and current therapies. *Clin Ther* 1998 **20**: 40–57.
3. Scully C, El Kabir M, Samaranyake LP. Candida and oral candidosis: a review. *Crit Rev Oral Biol Med* 1994 **5**: 125–157.
4. Shay K, Truhlar MR, Renner RP. Oropharyngeal candidosis in the older patient. *J Am Ger Soc* 1997 **45**: 863–870.
5. Hedderwick S, Kauffman CA. Opportunistic fungal infections: superficial and systemic candidiasis. *Geriatrics* 1997 **52**: 50–59.
6. Budtz-Jorgensen E. Clinical aspects of *Candida* infection in denture wearers. *J Am Dent Assoc* 1978 **96**: 474–479.
7. Rodu B, Griffin IL, Gockerman JP. Oral candidiasis in cancer patients. *Southern Med J* 1984 **77**: 312–314.
8. Patton LL, Glick M. *Clinician's guide to the treatment of HIV-infected patients*. 3<sup>rd</sup> ed, pp 14–15 Baltimore: American Academy of Oral Medicine, 2001.
9. Patton LL, Bonito AJ, Shugars DA. A systematic review of the effectiveness of antifungal drugs for the prevention and treatment of oropharyngeal candidiasis in HIV-positive patients. *Oral Surg Oral Med Oral Pathol Oral Radiol Endod* 2001 **92**: 170–179.
10. Bernarde MA, Snow WB, Olivieri VP, et al. Kinetics and mechanism of bacterial disinfection by chlorine dioxide. *Appl Microbiol* 1967 **15**: 257–265.
11. Bell JA, Brockmann SL, Feil P, et al. The effectiveness of two disinfectants on denture base acrylic resin with an organic load. *J Prosthet Dent* 1989 **61**: 580–583.
12. Kenyon AJ, Hamilton SG, Douglas DM. Comparison of antipseudomonal activity of chlorine dioxide/chlorous acid-containing gel with commercially available antiseptics. *Amer J Vet Res* 1986 **47**: 1101–1104.
13. Chapek CW, Reed OK, Ratcliff PA. Management of periodontitis with oral-care products. *Compendium* 1994 **15**: 740–745.
14. Suh DH, Abdel-Rahman MS, Bull RJ. Effect of chlorine dioxide and its metabolites in drinking water on fetal development in rats. *J Appl Toxicol* 1983 **3**: 75–79.
15. Tuthill RW, Giusti RA, Moore GS, Calabrese EJ. Health effects among newborns after prenatal exposure to ClO<sub>2</sub> disinfected drinking water. *Environ Health Perspect* 1982 **46**: 39–45.
16. Gerges SE, Abdel-Rahman MS, Skowronski GA, Von Hagen S. Effects of alcide gel on fetal development in rats and mice. *J Applied Toxicol* 1985 **5**: 104–109.
17. Scatina J, Abdel-Rahman MS, Gerges SE, Alliger H. Pharmacokinetics of alcide, a germicidal compound in rat. *J Applied Toxicol* 1983 **3**: 150–153.
18. Williams DW, Lewis MA. Isolation and identification of *Candida* from the oral cavity. *Oral Diseases* 2000 **6**: 3–11.
19. Silwood CJL, Grootveld MC, Lynch E. A multifactorial investigation of the ability of oral health care products (OHCPs) to alleviate oral malodour. *J Clin Periodontol* 2001 **28**: 634–641.
20. Frascella J, Gilbert RD, Fernandez P, et al. Efficacy of a chlorine dioxide-containing mouthrinse in oral malodor. *Compendium* 2000 **21**: 241–248.